



Histopathological effect of different concentration of powder detergent on the laboratory mice (*Mus musculus*) intestine

Sundus M. Tayfur

Medical Laboratory-Techniques Department-Technical College-Kirkuk , Kirkuk , Iraq

ARTICLE INFO.

Article history:

-Received: 9 / 1 / 2018

-Accepted: 20 / 2 / 2018

-Available online: / / 2018

Keywords: Histopathological effect, Detergent powder, laboratory mice, Intestine .

Corresponding Author:

Name: Sundus M. Tayfur

E-mail:

Sundus_mta@yahoo.com

Tel:

Affiliation:

Abstract

Eighty mice (*Mus musculus*) were ingested with various concentration of powder detergent and the Histopathological changes were measured of different concentration of Powder detergent by ingesting 80 mice *Mus musculus* strain (4-8) weeks aged with detergent solutions. mice were divided into (8) groups ,each one composed of (8) mice. The control group (H) were ingested vegetables (celery) only, while the groups (A,B,C,D,E,F,G) were ingested vegetables (celery), which soaked in aqueous solution of Powder detergent with various concentrations of Powder detergent for different times (1.5g/Kg15min, 3g/Kg15min, 4.5g/Kg15min, 1.5g/Kg30min, 3g/Kg30min, 4.5g/Kg30min, 1.5 g/Kg1-2min). The intestine tissue of the exposed mice showed marked Histopathological changes induced in the intestine of mice by detergent included Many intestinal microvilli were ruptured near the tips, lesions of Epithelial cells of microvilli, Elongation of vili, Degeneration, Lymphocyte infiltration, vacuolation and Necrosis. The effects increased by increasing of concentration the detergent solutions Consecutively 4.5g/Kg30min, 3g/Kg30min and 1.5g/Kg30min, were, more than 4.5g/Kg15min, 3g/Kg15min and 1.5g/Kg15min and duration when compared to control (H) group. The results of this research have shown that the detergent is toxic to the mice exposed. the results of the study emphasize healthy hazards of detergent exposure, so needs a proper handling and disposal them during daily life using Finally, it is hoped that the result from this investigation will enlighten people on the health risk posed by detergent.

Introduction

Detergent is a surfactant or a mixture of surfactants with "cleaning properties in dilute solutions." [1] Detergents are On a large scale used in biochemistry, cell biology or molecular biology. It can be classified for instance according to the chemical structure according of polar and nonpolar group consistants (glucosides, alkyl ionic detergents, polyoxyethylene alcohols, bile salts, sulphonates etc.), the charge character (anionic, cationic, zwitterionic = amphoteric and nonionic) or simply whether they are mild or strong in terms of their soluble ability and / or to denature proteins [2]. They all in common have soluble amphipathic (amphiphilic) compounds, with both lipophilic (hydrophobic, nonpolar) and lipophobic (hydrophilic, polar) sites within one molecule [3]. The increasing domestic health risks and environmental pollution arising from detergent

exposure are reducing the popularity of benefit [4]. Toxic materials cause tissues damage and histopathological degradations in the intestine of animals [5]. But most of the health hazards are caused by lack of information on the toxicity of detergents which makes people to handle or Get rid of detergents carelessly [6]. Reagent grade detergents are employed for the isolation and purification of integral membrane proteins found in biological cells. [7] Dissolution of cell membrane bilayers demand a detergent that can enter the inner membrane monolayer [8]. Therefore, the present study was aimed to determine the effect of oral administration of Detergent on mice intestine.

Objective: Evaluate the effect of the treatment with the multiple dose of detergent on the Intestine of the mice .

Materials and Methods

Test substance: Chemical Components of the detergent include surfactants, sodium sulfate, sodium carbonate, optical brighteners, phosphate, polycarboxylates and enzymes.

1. Animals management:

Healthy, adult mice of *Mus musculus* strain were used in this study, ranging age was between (4-8) weeks old and their weight were about (25±2g) . Animals were divided into eight equal groups (each group consisted of 10 mice). These animals were kept in an air condition room at a temperature of (22-24 °c), with about (12-14) hours of day light exposure. Animals were housed in cages measuring (29*15*12cm) and each 10 animals were kept in on cage contained wooden shave. Water and feed

composed of (bread and vegetables) were freely excess able and animals were kept for at least two weeks for adaptation. Animal cages were cleaned and sterilized with 70% ethanol once a week regularly according to the procedure mentioned by [9].

2 .Experimental Design:

The detergent management protocol (the concentration, route of administration and interval of administration) was followed according to standard procedure [10] & [11]. Mice were divided into eight equal groups; where seven groups o were ingested orally with detergents at the beginning of the week and were autopsied for liver examination after (18 weeks) .While , the control group (H) was ingested orally only with bread and water.

Table (1): Detergent administration protocol

Group number	Number of mice	Total concentration of detergent /does	Exposure time (minute)	Time of Autopsy /week
A	10	1.5g/Kg	15min	After 18 weeks
B	10	3 g/Kg	15min	After 18 weeks
C	10	4.5 g/Kg	15min	After 18 weeks
D	10	1.5 g/Kg	30min	After 18 weeks
E	10	3 g/Kg	30min	After 18 weeks
F	10	4.5 g/Kg	30min	After 18 weeks
G	10	1.5 g/Kg	1-2min	After 18 weeks
H	10	no	no	After 18 weeks

Histological assessment

Intestine tissue were fixed in 10% formalin and were embedded in paraffin .Tissue sections were made at 5mm,mounted on slides, stained with hematoxylin-eosin (H-E) for general intestine structures examination. The sections were examined using light microscope (Optika-Italy) and photographed with (I phone 5- camera) according to standard procedures [12].

Result

Previously, it is apparent that the test animal of the present study has Showed that the vital organs were damaged at cellular level due to the effect of detergent. Many intestinal villi were torn near the tips and cellular exudates were also observed. Enlarged mucous cells filled with secretory materials were observed. Proliferations of mucous epithelial cells. The whole cutoff of epithelia became discrete and the mucosal cells were found in a highly disintegratcondition, vacuolation and lesions of Epithelial cells of villi, The effects increased by increasing of concentration and duration when compared to control. Control group that showed

histological examination of the intestinal tissue layers involved, Serosa (S1);Subserosa (S2); Submucosa (S3); Muscularis mucosa (M1); Gastric mucosa (M2).

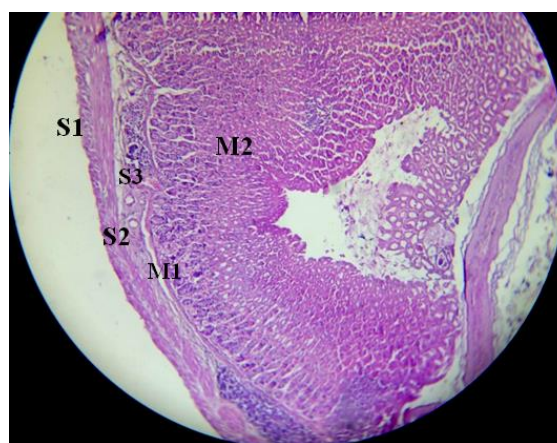


Figure 1: Intestine section of control intestine involved, Serosa (S1); Subserosa (S2); Submucosa (S3); Muscularis mucosa (M1); Gastric mucosa (M2), (H&E,40X)

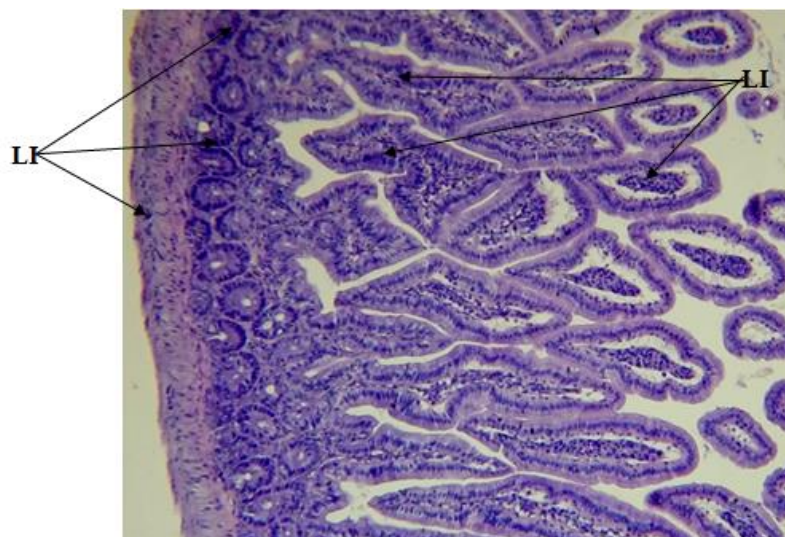


Figure 2: Intestine section of treated mouse with (1.5gm) 15 min. has Lymphocyte infiltration(LI) , (H&E,400X)

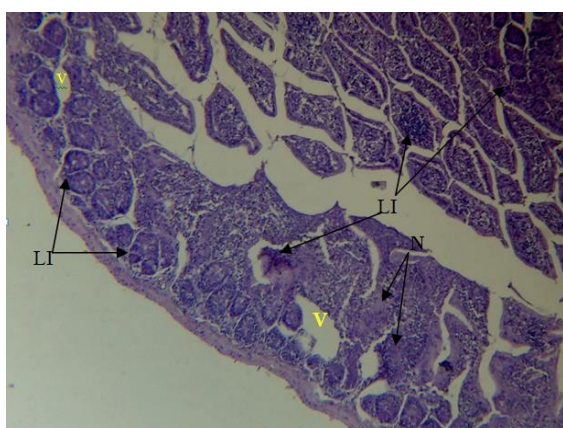


Figure 3: Intestine section of treated mouse with (1.5gm) 30 min. has Vacolation(V), Lymphocyte infiltration(LI)& Necrosis(N) (H&E ,400X)

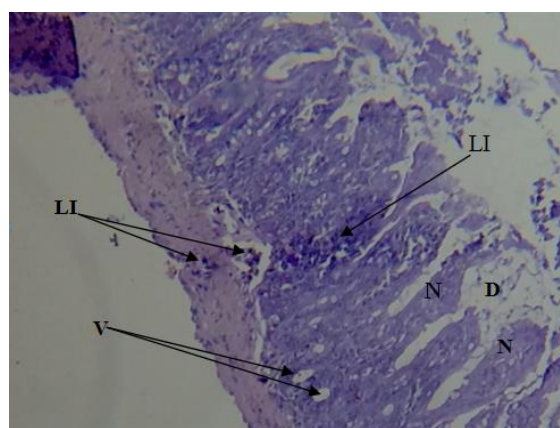


Figure 5: Intestine section of treated mouse with (3gm) 30 min. has Vacolation(V), Lymphocyte infiltration(LI)& Necrosis(N) (H&E ,400X)

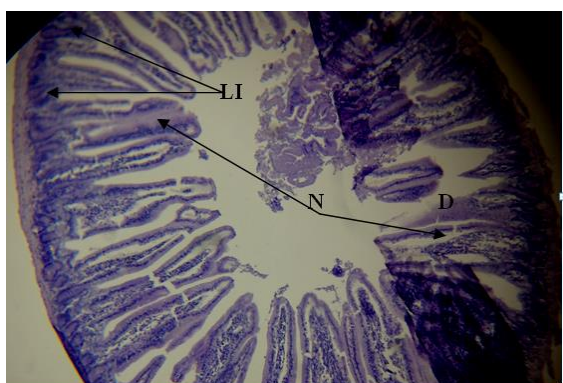

Figure 4: Intestine section of treated mouse with (3gm) 15 min. has Elongation of vili, Degeneration (D), Lymphocyte infiltration(LI)& Necrosis(N) (H&E ,400X)

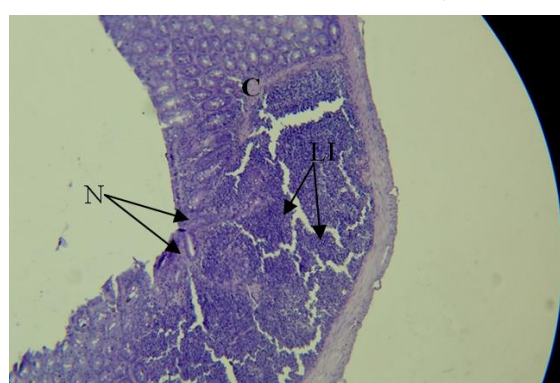

Figure 6: Intestine section of treated mouse with (4.5g) 15min. has Congestion(C), Lymphocyte infiltration(LI)& Necrosis(N) (H&E ,40X)

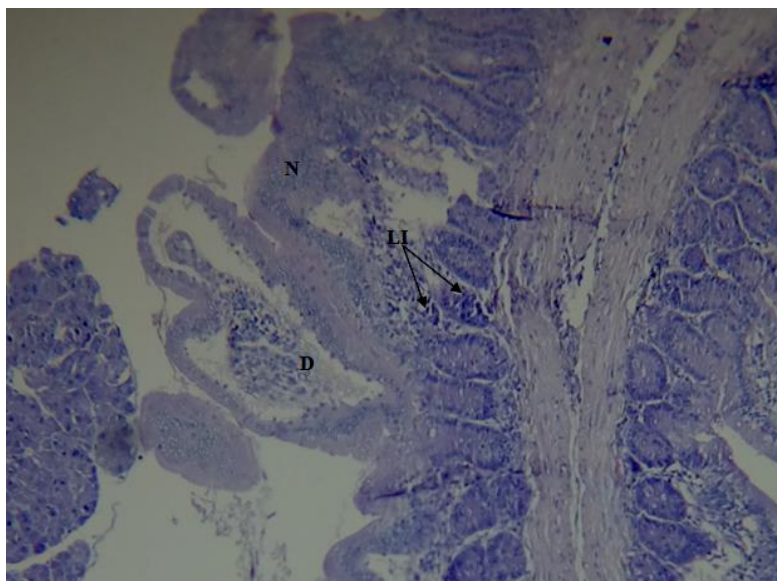


Figure7: Intestine section of treated mouse with (4.5g) 30 min. has Lymphocyte infiltration(LI), Degeneration(D), Necrosis(N) & Elongation of villi (H&E ,400X)

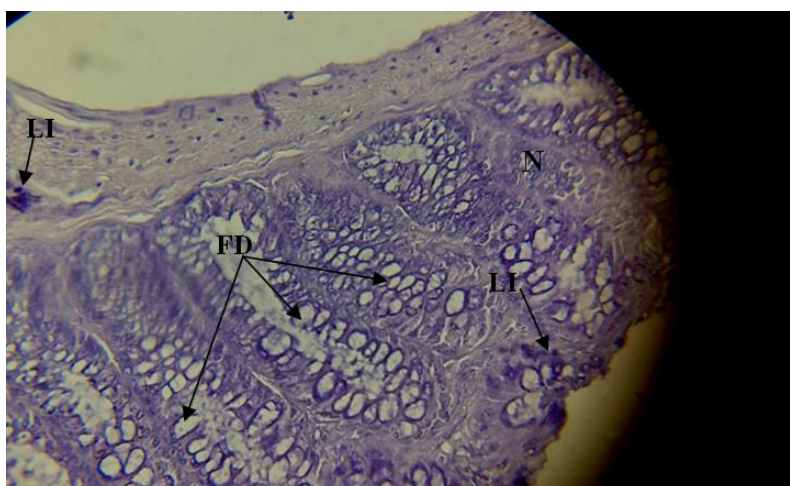

Figure 8: Intestine section of treated mouse with (1.5g) 1-2 min. has Necrosis (N), Lymphocyte Infiltration(LI) & Fatty of Degeneration(FD) (H&E ,400X)

Discussion

Influence of detergent on the exposed mice may be due to the irritation of the Gastrointestinal tract of the mice caused by the ingestion [13]. High concentration of detergent reduced the food exhaustion and the weight of animals [8]. A study was confirmed that, chronic exposure of detergent also reduced food consumption and lateness the growth of the sea bass larvae [14]. However, the result did not observe any important reduction in the growth, [15]. Intestine of the Studied mice showed a marked histopathological changes promoted that the detergent has an prejudicial effect on the mice. The histopathological changes were as a result of cytotoxic agents [16] in the detergent solution which caused multi organs injuries. Intestinal metaplasia is associated with the transformation of the stomach lining and in the earlier stages, the replaced epithelium resembles the small intestine [17]. There is no acquaintance on the causes of the intestinal metaplastic disorder has been obtained so far [17].

However, medical expert affirm that gastroesophageal bounce disease, a status in which the acid content of stomach could lead to metaplasia of the stomach [18]. The result supports research existing that ingestion of detergent solution can cause multi organ damage leading to nervous system disorders, respiratory illness, cancer and death [19,20]. The result is in line with reported pathological changes in animal and plant exposed to detergent [21,22]. This study did not determine cancer changes which has been suspected by some prospectors [23], probably due to the short duration of the study. Potassium hydroxide and sodium silicate, a most components of soap has been fingered in gastrointestinal commotion leading to nausea, severe digestive tract burns and weight loss in an exposed animal was observed [23,24]. Laceration of tips villi observation in the present case may be regarded as a mode of detoxification to get eliminate of intestine; as proposed [25]. Another cellular damage including oedema may be associated with the

release of acid hydrolases from lysosomes guidance to the autolysis of cell. Spoilage inflicted in mucosa, more especially the villi are of special concern since villus is the working unit of intestine and it is the villi that the inner ends of absorptive cells come in contact with blood and lymph which pick up absorbed nutrient to carry them to other parts of body. The function of villi is so significant and damages at this site in the present case being so severe the extent of

References

1. Ronni, W. Detergent Chemistry : Foundation and Application: Encyclopedia . Com. Accessed 15 may ,2011 at <http://www.Encyclopedia.Com>. 2004.
2. Chun, W.C and H.Z. You, Nonionic surfactant Brij35 effectson toluene biodegradation in a composite bead bio-filter. *Afr. J. Biotechnol.* 2009, 8:5406-5414.
3. Abulude, F.O. Ogunkoya, R.F. Ogunleye, O. Emidun and A.I. Abulude Assessment of the content of Pb, Cd ,Ni and Cr in soap and detergent from Akure. *Nigeria. Res. J. Environ. Toxicol.* 2007, 1:102-104.
4. Ezemonye, L. and A. Enuneku. Evaluation of acute toxicity of cadmium and lead to amphibian tadpole (Toad: *Bufo maculatus* an frog: *ptyadena bibroni*) and frog. *J. Aquat. Sci.* 2005, 20: 33-36.
5. Rathee Radha. Effect of Detergent on Histology of Fish Intestine. 2015 *IJSRR*, 4(1), 07 - 15.
6. Easy Essay Effects of laundry detergent on the environment. <http://ez-essay.Blogspot.com /2007/12/effects-of-laundry-detergent-on.html>, 2007.
7. Ayandiran, T.A.,O.O Fawole, S.O. Adewoye and M.A. Ogunddiran. Bio-concentration of metals in the body musle and gut of *Clarias gariepinus* exposed to sub-lethal concentrations of soap and detergent effluent. *J. Cell Anim. Biol.* 2009, 3: 113-118.
8. Wadaan, M.A.M. and M.Mubarak. Blood chemistry changes as an evidence of the toxic effects of anionic surfactant sodium ddisulfate . *Asian J. Scientific Res.* 2009, 2:113-118.
9. Ojo, O.A. Oso. Biodegradation of synthetic detergents in wastewater . *Afr. J. Biotechnol.* 2009, 8: 1090-1109.
10. Ogunbileje, J.O. and O.M. Akinosun. Biochemical and hematological profile in Nigeria cement factory workers. *Res. J. Environ. Toxicol.* 2011.
11. Warne, M.J .St and A.D. Schifko,. Toxicity of laundry detergent components to a freshwater cladoceran and their contribution to detergent toxicity. *Ecotoxicol. Safety.* 1999, 44: 196-206.
12. Wadaan, M.A.M. and M. Mubarak. Blood chemistry changes asa an evidence of the toxic effects of anionic surfactant sodiumddisulfate. *Asian J. Scientific Res.* 2009, 2: 113-118.
13. Esenowo IK, Ugwumba OA. Growth response of cat fish (*Clarias gariepinus*) exposedto water soluble fraction of detergent and diseal oil. *Environmental Research Journal.* 2010;4:298-301.
14. Rejeki S, Desrina D, Mulgana RA. Chronic effect of detergent surfactant linear alkylbenzene sulfonate on the growth and survival rate of sea bass (*Lates Calcalifer Block*) larvae. *Agriculture Study Program Fisheries Department, Faculty of Fisheries and Marine Science, Diponegaro University, Semarang, Indonesia.* 2006;1-18.
15. Faremi AY, Oloyede OB. Biochemical assessment of the effect of soap and industrial effluent on some enzymes in the stomach of albino rats. *Research Journal of Environmental Toxicology.* 2010;4:127-133.
16. Ogunbileje JO, Akinosun MO. Biochemical and hematological profile in Nigeria cement factoring workers. *Research Journal of Environmental Toxicology.* 2011;4:123-157.
17. Madhulima A. Intestinal Metaplasia; 2016. (Accessed on 12th October, 2016) Available: www.hxbenefit.com/inestinalmetaplasia.html
18. Ayandiran TA, Fawole OO, Adewoye SO, Ogundiran MA. Bio-concentration of metal in the body muscle and gut of *Claris gariepinus* exposed to sub lethal concentration of soap and detergent effluent. *Journal of Cell and Animal Biology.* 2009; 3: 113-118.
19. Gholami M, Fatemi SMR, Falahi M, Esmaili A, Mashinchian A. Effect of heavy metal (copper and cadmium) and detergent on white fish fry *Rutilus frisiikutum*. *Research Journal of Environmental Toxicology.* 2010;4:231-236.
20. Akanji MA, Olagoke OA, Olayode OB. Effect of chronic consumption of metal bisulphateon the integrity of rat liver cellular system. *Toxicity.* 1993; 81:173-179.
21. Uaboi-Egbenni PO, Okolie PN, Adejuyitan OE, Sobande AO, Akinyemi O. Effect of industrial effluents on the growth and anatomical structures of *Abelmoschus esculentus*. *African Journal of Biotechnology.* 2009;8:3251-3260.
22. Kassem N. Allergens and toxin in laundry detergent: Synthetic Ingredient that are Harmful to People and the Environment; 2010. (Accessed on 3rdFebruary, 2015) Available: <http://organizedwisdom.com/allergens-and-toxins-in-laundry-detergentssynthetic-ingredient-that-are-harmful-topeople>.
23. Warne MJ, Schifko AD. Toxicity of loundary detergent components to a fresh water cladoceran and their contribution to detergent toxicity. *Ecotoxicology and Safety.* 1999;44:196-206.

24. Wadaan MA, Mubarak M. Blood chemistry changes as an evidence of the toxic effect of anionic surfactant dodecyl sulphate. Asian Journal of Scientific Research. 2009; 2:113-118.

25. Van Dyk GM, Pieterse JHJ, and Vuren M. Histological changes in the liver of Oreochromis mossambicus (Cichlidae) after exposure to Cadmium and zinc. A review of Ecotoxicology and Environmental Safety. 2005; 2 (1): 1-9.

26. Maciorowski A F, Dolan J M. and Gregg B C. Histological damage and recovery of Pisidium castertanum exposed to linear tridecyl benzene sulfonate, and anionic surfactant. Comp

Biochem Physiol. 1997; 56: 117-122.

27. Ogochukwu NH and Joseph CI. Toxicity of crude oil product and detergent on serum alkaline phosphatase concentration of Clarias gariepinus juveniles. Animal Research International. 2009; 6:1045-1048.

28. Travlos G S, Morris R W, Elewell M R, Duke A, Rosenblum S, and Thompson M B. Frequency and relationship of clinical chemistry and liver and kidney histopathology finding in 13 week toxicity study in rats. Toxicology. 1996; 107: 17-29.

التأثيرات المرضية والنسجية للتراكيز المختلفة لمسحوق التنظيف على امعاء الفئران المختبرية

Mus musculus

سندس محمد طيفور عبد العزيز

قسم التحليلات المرضية ، الكلية التقنية- كركوك ، كركوك ، العراق

الملخص

تم دراسة التأثيرات المرضية والنسجية للتراكيز المختلفة للمنظفات عن طريق معاملة 80 فار بأعمار (4-8) اسابيع مع محلول المنظفات. تم تقسيم الفئران الى ثمانية مجاميع لكل مجموعة 10 فئران سلالة *Mus musculus*. مجموع السيطرة المتمثلة بمجموعة (H) عوملت من خلال اطعامها بالخضراوات (الكرفس) المنقع بالماء، في حين تم اطعام بقية المجاميع (A,B,C,D,E,F) من خلال تتقيع الكرفس بالتراكيز المختلفة كل حسب المجاميع وعلى فترات مختلفة لكل تركيز (1.5g/Kg 15min ، 3g/Kg 15min ، 4.5g/Kg 15min ، 1.5g/Kg 30min ، 3g/Kg 30min ، 4.5g/Kg 30min). اظهرت التأثيرات المرضية والنسجية لامعاء الفئران الكثير من التغيرات الناجمة من تأثير محاليل مسحوق التنظيف والتي تمثلت بتلف وتساقط الزغيبات المعوية مع ظهور افات نسجية اخرى في الطبقة الظهارية للامعاء تمثلت باستظلة في الزغيبات وتحلل البعض الاخر اضافة الى ارتشاح للخلايا للمفاوية في جميع المجاميع مع حدوث تحجج ونخر في بعض من المجاميع المعاملة وازدادت شدة التأثير بزيادة التراكيز كما هو موضح 4.5g/Kg 30min ، 3g/Kg 30min ، 4.5g/Kg 15min ، 1.5g/Kg 15min مقارنة مع مجموعة السيطرة. وقد أظهرت نتائج هذا البحث أن المنظفات سامة للفئران المعاملة وكدت نتائج الدراسة الى المعالجة السليمة والتخلص الامن من المنظفات اثناء استعمال المنظفات في الحياة اليومية. وأخيرا، يؤمل أن تؤدي نتيجة هذه الدراسة إلى تنوير الناس على المخاطر الصحية التي يشكلها المنظفات.

الكلمات المفتاحية: التأثيرات المرضية والنسجية ،مسحوق تنظيف باودر، فئران مختبرية ،امعاء الفئران .